

See discussions, stats, and author profiles for this publication at: <https://www.researchgate.net/publication/358590218>

# Role of Magnetic Resonance Imaging in Diabetic Foot: A Cross-sectional Study

Article in *Journal of Clinical and Diagnostic Research* · January 2022

DOI: 10.7860/JCDR/2022/51508.15918

---

CITATIONS

0

READS

12

5 authors, including:



Uma Narayanamurthy

Mahatma Gandhi Medical College and Research Institute

8 PUBLICATIONS 0 CITATIONS

SEE PROFILE

Some of the authors of this publication are also working on these related projects:



Nephroprotective effect of silymarin in hyperglycemia-induced oxidative stress in rats [View project](#)

# Role of Magnetic Resonance Imaging in Diabetic Foot: A Cross-sectional Study

SHRIRAM THAMARASELVAN<sup>1</sup>, JAYAKRISHNAN RAMANKUTTY JAYAKUMAR<sup>2</sup>, SHIBU POTTAYIL<sup>3</sup>, SRIKANTH MOORTHY<sup>4</sup>, UMA NARAYANAMURTHY<sup>5</sup>



## ABSTRACT

**Introduction:** Diabetes related foot problems like osteomyelitis and Charcot (neuro-osteoarthropathy) are associated with high morbidity and high healthcare costs. Soft tissue and bone infection involving the foot is particularly common in patients with diabetes mellitus. Osteomyelitis and neuropathic osteoarthropathy often co-exists in diabetes. Differentiating between these two entities is often difficult but crucial as the management may differ significantly.

**Aim:** To assess the role of Magnetic Resonance Imaging (MRI) in diabetic foot and its ability to identify features which help to reliably differentiate infection from neuropathy and to describe the MRI imaging findings of infection and neuropathic changes in diabetic foot.

**Materials and Methods:** The present cross-sectional study was conducted in Amrita Institute of Medical Sciences and Research Centre, Kochi, Kerala, India, from June 2013 to October 2015. All diabetic patients with suspected osteomyelitis or charcot who were referred for MRI were included. MRI was interpreted based on the following parameters location, distribution of oedema

pattern, deformity, soft tissue changes and bone marrow signal change. Forty eight patients with diabetic foot, who underwent foot surgery with debridement or drainage and MR findings of the patient were compared with histopathology or culture respectively. Comparison of MR findings were also done with Computed Tomography (CT)/Positron Emission Tomography (PET) wherever available.

**Results:** In this study, MRI findings with focal single bone involvement along with diffuse marrow oedema pattern, absence of deformity, forefoot/hindfoot location, presence of soft tissue changes like ulcer/sinus tract/fistulas and abscess formation were in favour of osteomyelitis. Several bones and joints involvement along with subchondral/periarticular location, presence of deformity, absence of soft tissue changes and midfoot location were in favour of Charcot's.

**Conclusion:** The MRI was found to be the most reliable and sensible tool for imaging techniques to differentiate osteomyelitis with diabetic neuropathic arthropathy, with the sensitivity and specificity of MRI as 83.3% and 77.8%, respectively.

**Keywords:** Charcot disease, Foot magnetic resonance imaging, Neuropathic joint, Osteomyelitis, Ulcer of foot

## INTRODUCTION

Diabetes related foot problems like osteomyelitis and charcot are associated with a high morbidity and high healthcare costs. A highly specific and remarkable diagnostic tool is mandatory to identify the exact cause of the patients with red hot foot, which is one of the day to day Outpatient Department challenges faced by the physicians and the radiologist in a diabetic foot diagnosis. Since diabetic mellitus and neuropathic osteoarthropathy often co-exists and irreplaceable diagnostic technique is also the need of the hour. Early and accurate diagnosis of foot infection and appropriate therapy such as antibiotics and surgical debridement is necessary, thereby avoiding future complications [1]. Charcot's joint, on the other hand, requires management primarily by off loading, anti-resorptive therapy, bone growth stimulation or surgery for deformity correction [2]. Plain radiography, a low-cost modality, is the first imaging technique used to evaluate bone infection. However, osseous changes are usually delayed for 1-2 weeks after the onset of infectious disease.

Bone scintigraphy has high sensitivity but poor spatial resolution for osteomyelitis. Furthermore, scintigraphy results are negative when there is poor blood supply [3]. Recent studies have also shown (18<sub>p</sub>)-2-Fluoro-2-Deoxy-D-Glucose (FDG)-PET to be highly specific imaging modality for diagnosis of osteomyelitis [4]. MRI has proven to be effective in the assessment of osteomyelitis with very high accuracy [5]. This technique can detect subtle changes in soft tissues, however the diagnosis is difficult due to superimposed neuropathic osteoarthropathy. Bone biopsy, which includes histopathology and culture, remains the gold standard of reference, despite being an invasive technique [3].

A study by Enderle MD et al., had shown MRI to have a specificity of 75%, sensitivity of 100%, Positive Predictive Value (PPV)-93%, Negative Predictive Value (NPV)-100% when compared to other modality's like plain film radiography, bone scintigraphy, however diagnosis of osteomyelitis and differentiating it from neuro-osteoarthropathy and charcot with superimposed infection still remains a challenge [6]. Hence, the present study was conducted with following objectives:

1. Role of MRI in diabetic foot and its ability to identify features which help to reliably differentiate infection from neuropathy.
2. To describe MRI findings of infection and neuropathic changes in diabetic foot.

## MATERIALS AND METHODS

This cross-sectional study after approval from the Ethics Committee of Amrita Institute of Medical Sciences and Research Centre, Kochi, Kerala, India (Dissertation Review/MD/MS/2013/22), was conducted from June 2013 to October 2015. An informed consent was obtained from all the patients participating in the study. All the patients were informed that the radiological examination was primarily for clinical and secondarily for radiological research.

**Sample size calculation:** Based on the results on the sensitivity and accuracy of MRI with histopathology/culture from earlier publication [7] and with 95% confidence and 20% allowable error minimum sample size came to 25. Total 48 patients were enrolled in the study.

**Inclusion criteria:** All patients of suspected diabetic foot syndrome who are referred for MRI were included in the study.

**Exclusion criteria:** Patients with foot ulcers and gangrene due to non diabetic vascular cause, claustrophobic patients were excluded from the study.

**Equipment used:** MRI- GE medical systems, Milwaukee, Wisconsin- 1.5 Tesla HDXT.

### Image Acquisition

In attempting to differentiate between suspected infections from neuropathic osteoarthropathy, high resolution, and small field of view studies were used [1,2]. The images were obtained with a small field of view (8-10 cm), with thin sections (3-4 mm) to optimise spatial resolution. The routine examination was performed with patient lying supine and foot positioned in extremity coil. The foot is normally placed in neutral position. The scan planes are tailored for each individual examination [1]. A minimum of two planes were obtained. Gadoversetamide (optimark) is used as contrast at a dose of 0.1 mmol/kg [Table/Fig-1].

Parameters	Axial T1W	SAG T1W	STIR AXIAL	STIR SAG	STIR CORONOL	SAG T2	GAD T1+C
TR	600	612	4925	4925	4925	5419	600
TE	15	15	50	50	50	102	15
FOV	20	24	24	24	24	24	24
Slice thickness	4	3	4	4	4	4	4

**[Table/Fig-1]:** Sequences used in MRI.

TR: Repetition time; TE: Time of echo; FOV: Field of view; STIR: Short tau inversion recovery; GAD: Gadolinium; SAG: Sagittal

### Image Interpretation

The MRI was interpreted by a trained radiologist based on the following parameters.

Six variables were taken into consideration, which were:

1. Bone marrow oedema changes.
2. Distribution of osteomyelitis and charcot with diabetic foot.
3. Presence or absence of deformity.
4. Location of the osteomyelitis and neuroarthropathy within diabetic foot.
5. Presence or absence of soft tissue changes like sinus tracts/fistulas/abscess.
6. Comparison of changes in signal intensity in the diabetic foot.

With the help of these variables [1,3], diagnosis of osteomyelitis or charcot was made and it was compared with surgery (bone biopsy)/PET scan whichever was available.

### STATISTICAL ANALYSIS

The observations were recorded and analysed using International Business Machines (IBM) Statistical Package for the Social Sciences (SPSS) version 20.0 software for Windows. Validity parameters like sensitivity, specificity and accuracy of the key MRI findings in differentiating infection from neuropathy of diabetic foot was computed. Statistical significance of the factors which are associated with diabetic foot syndrome was tested by Fisher's exact test.

### RESULTS

Out of 48 patients enrolled in the study, 36 (75%) were males and 12 (25%) were females and maximum number of patients were in the age group of 51-60 years [Table/Fig-2].

Age group (years)	Male	Female	Total
31-40	1	0	1
41-50	2	2	4
51-60	13	4	17
61-70	12	4	16
71-80	8	2	10
Total	36	12	48

**[Table/Fig-2]:** Age and sex wise distribution of the patient.

Out of 48 patients, 29 patients (60.4%) showed growth (osteomyelitis) in which 25 cases (83.3%) were diagnosed in MRI, 19 patients (39.6%) did not show growth (charcot's disease) out of which MRI was able to diagnose 14 cases (77.8%) [Table/Fig-3].

MRI findings	Growth/PET scan Yes, n (%)	Growth/PET scan No, n (%)	p-value
Osteomyelitis	25 (83.3)	4 (22.21)	1.000
Charcot	5 (16.7)	14 (77.8)	

**[Table/Fig-3]:** MRI in osteomyelitis and charcot in comparison with PET scan/growth.

### Variables for Analysis to Differentiate Osteomyelitis from Charcot

**1. Bone marrow oedema changes in diabetic foot:** This study showed 18 out of 19 cases of Charcot's disease showed subchondral and periarticular involvement in MRI. Out of 29 cases majority of cases (55.2%) showed single bone. There existed highly significant association between the bone marrow oedema pattern in charcot and osteomyelitis [Table/Fig-4].

Bone marrow oedema changes	Single bone	Subchondral and periarticular	p-value
Osteomyelitis	16 (55.2%)	13 (44.8%)	<0.001
Charcot	1 (5.3%)	18 (94.7%)	

**[Table/Fig-4]:** Bone marrow oedema changes in charcot's disease and osteomyelitis. Fisher's-exact test; p-value <0.05 is statistically significant

**2. Distribution of charcot's and osteomyelitis within diabetic foot:** This study showed 18 out of 19 cases of Charcot's disease showed several bones and joint involvement in MRI. Out of 29 cases majority of cases (65.5%) showed focal/single bone involvement. There existed highly significant association for distribution of bone marrow oedema pattern between charcot and osteomyelitis [Table/Fig-5].

Distribution	Focal/Single joint or Bone, n (%)	Several bone and joints, n (%)	p-value
Osteomyelitis	19 (65.5)	10 (34.5)	<0.001
Charcot	1 (5.3)	18 (94.7)	

**[Table/Fig-5]:** Distribution of charcot's disease within diabetic foot. Fisher's-exact test; p-value <0.05 is statistically significant

**3. Role of deformity in diabetic foot:** This study showed 16 out of 19 cases of Charcot's disease showed deformity in MRI. Out of 29 cases of osteomyelitis 75.9% showed no deformity. There existed highly significant association between the presence and absence of deformity in charcot's disease and osteomyelitis [Table/Fig-6].

Deformity	Yes, n (%)	No, n (%)	p-value
Osteomyelitis	7 (24.1)	22 (75.9)	<0.001
Charcot	16 (84.2)	3 (15.8)	

**[Table/Fig-6]:** Role of deformity in diabetic foot in charcot's disease and osteomyelitis. Fisher's-exact test; p-value <0.05 is statistically significant

**4. Location of osteomyelitis and charcot in diabetic foot:** In this study, majority of the cases of osteomyelitis was commonly seen in hind foot/forefoot with about 25 out of 29 cases [Table/Fig-7]. Only 4 cases (13.8%) had midfoot predilection for osteomyelitis making it a reliable indicator. There existed highly significant association between the locations charcot's disease and osteomyelitis in diabetic foot.

Location	Forefoot/Hindfoot (n=26)	Midfoot (n=9)	Both (n=13)	p-value
Osteomyelitis	20 (69%)	4 (13.8%)	5 (17.2%)	0.038
Charcot	6 (31.6%)	5 (26.3%)	8 (42.1%)	

**[Table/Fig-7]:** Location of charcot's disease and osteomyelitis in diabetic foot. Fisher's-exact test; p-value <0.05 is statistically significant

**5. Presence or absence of soft tissue changes in diabetic foot:** This study showed 24 out of 29 cases of osteomyelitis showed

sinus tract, ulcer, fistulas and abscess involvement in MRI. Out of 19 cases majority of cases did not show features of ulcer, sinus tract or fistulas in MRI. There existed highly significant association between the soft tissue changes in charcot's disease and osteomyelitis in diabetic foot [Table/Fig-8].

Soft tissue changes	Ulcer/Sinus tract/ Fistulas present, n (%)	Ulcer/Sinus tract/ Fistulas absent, n (%)	p-value
Osteomyelitis	24 (82.7)	5 (17.3)	0.013
Charcot	9 (47.4)	10 (52.6)	

**[Table/Fig-8]:** Presence or absence of soft tissue changes in charcot's disease and osteomyelitis in diabetic foot. Fisher's-exact test; p-value <0.05 is statistically significant

**6. Signal intensities in diabetic foot:** This study showed 22 out of 29 cases of osteomyelitis showing low signal on T1 weighted MRI in MRI. Sixteen out of 19 cases of charcot's disease showed low signal in T1 weighted MRI. The correlation between the associations of signal changes in the diabetic foot was not significant in charcot's disease and osteomyelitis [Table/Fig-9].

Bone marrow signal change	High, n (%)	Low, n (%)	p-value
Osteomyelitis	7 (24.1)	22 (75.9)	0.719
Charcot	3 (15.8)	16 (84.2)	

**[Table/Fig-9]:** Signal intensities in charcot's disease and osteomyelitis in diabetic foot. Fisher's-exact test; p-value <0.05 is statistically significant

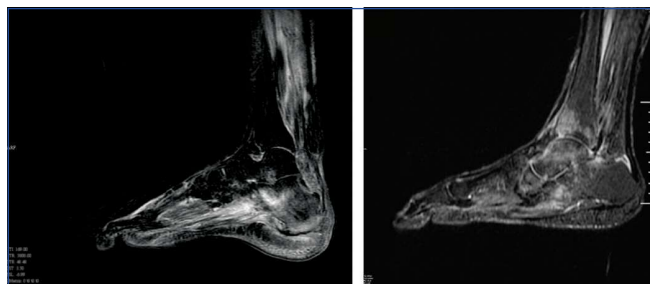
## DISCUSSION

This study consisted of 48 diabetic patients with foot infection. Out of these 48 patients, MRI detected 29 cases as osteomyelitis and 19 cases as charcot. Forty-six patients out of 48 patients had undergone bone biopsy and two patients had undergone PET scan. Thirty cases of these 48 cases were diagnosed as osteomyelitis and 18 cases were diagnosed as charcot on bone biopsy/PET scans which are considered as gold standards. Study by Tan PL and Teh J and Marcus CD et al., have also taken these variables into consideration [1,3].

**1. Presence or absence of deformity in diabetic foot:** "Ghost sign" was found to be a useful finding to differentiate the osseous findings in osteomyelitis and charcot. It is described that on T1 weighted images bones will "disappear" and then they "reappear" on contrast weighted T2 images. Tan PL and Teh J in their study had described that the presence of deformity is the commonest finding in the neuropathic arthropathy which was proved significantly with the present study [1].

**2. Oedema pattern in the diabetic foot:** Statistical analysis (Fisher t-Test) showed a good correlation  $p=0.007$  for distribution of oedema at the subchondral/ periarticular region favouring charcots and single bone involvement points more towards osteomyelitis ( $p<0.001$ ).

The charcot is primarily the articular disease [Table/Fig-10,11] hence oedema was more seen in juxta articular/subchondral region whereas in osteomyelitis it is generally greater in one side of the joint.



**[Table/Fig-10]:** Sagittal STIR image showing focal diffuse marrow oedema involving the calcaneum (single bone) in a case of calcaneal osteomyelitis.

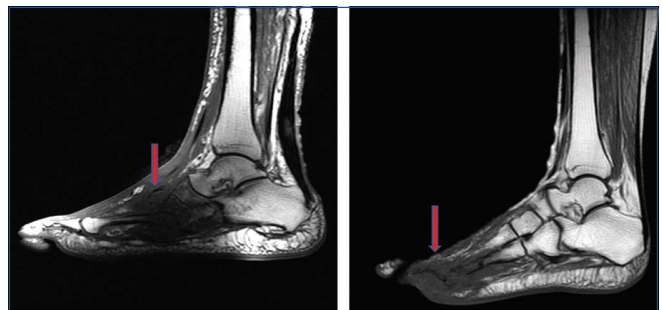
**[Table/Fig-11]:** Sagittal STIR image showing hyperintense marrow oedema involving several bones and joints in neuropathic osteoarthropathy. Also note the involvement of periarticular and subchondral regions. (Images from left to right)

Earlier study conducted by Tan PL and Teh J is also in concordance with present study which showed the predominance of single bone with diffuse marrow involvement in osteomyelitis and subchondral and periarticular involvement more common in charcot's disease which was significantly proved in this study [1].

**3. Distribution of osteomyelitis and charcot in diabetic foot:** In present study there was a good correlation of distribution of oedema pattern with osteomyelitis and charcots with diabetic foot with highly significant p-value of  $<0.001$  for both osteomyelitis and charcots. Lendermann HP et al., also found in his study, that focal involvement was in favour of osteomyelitis in diabetic foot and this can also be explained by the fact that the pathologic process in charcot's disease is joint centered compared to osteomyelitis in diabetic foot which was identified in this study on evaluation [8].

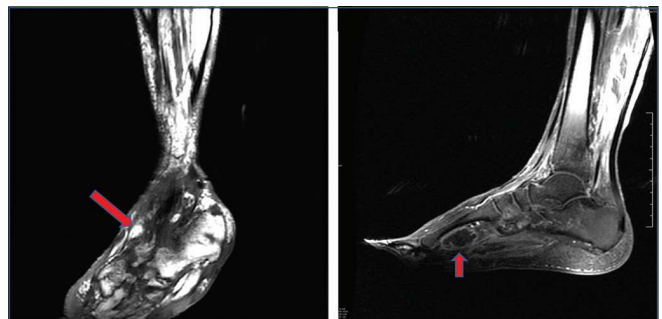
**4. Location of osteomyelitis and neuropathic arthropathy within the diabetic foot:** This study had showed [Table/Fig-7] that midfoot involvement (68.42%) [Table/Fig-12,13] being more common in charcot. A highly significant p-value of 0.038 for both osteomyelitis and charcot suggestive of good correlation on MRI. Earlier study conducted by Donovan A and Schweitzer ME showed that osteomyelitis was commoner in weight bearing areas [9]. Friction occurs in weight bearing areas leading to callus formation and then ulcer which acts as a precursor for abscess/sinus tract formation. Another study conducted by Marcus CD et al., also showed pathology of charcot starts in medial column i.e., midfoot and then progresses laterally [3]. Subluxation usually starts at the second metatarsal joints. This study shows the midfoot joint disruption and disorganisation (arrow) along with induration of soft tissue in a diabetic neuroarthropathy [Table/Fig-14].

**5. Comparison of soft tissue changes like ulcer/sinus tract/ fistulas or abscess:** The soft tissues changes were in good correlation with osteomyelitis and charcot [Table/Fig-8,15,16] on MRI with p-value of 0.013, making it a reliable indicator. Several studies conducted by Morrison WB et al., Tang JS et al., and Craig JG et al., showed predominance of soft tissue changes is more



**[Table/Fig-12]:** Sagittal T1 weighted image demonstrating the midfoot involvement (arrow) with deformity in case of charcot joint.

**[Table/Fig-13]:** Sagittal T1 weighted images showing T1 hypointense signal involving the forefoot (arrow) namely the head and body of metatarsals in a case of osteomyelitis. (Images from left to right)



**[Table/Fig-14]:** Sagittal T1 weighted image showing midfoot joint disruption and disorganisation (arrow) along with induration of soft tissue in a diabetic neuroarthropathy.

**[Table/Fig-15]:** Abscess and osteomyelitis. Sagittal T1 weighted image following intravenous gadolinium showing the rim enhancement of a collection adjacent to the metatarsal head. (Images from left to right)

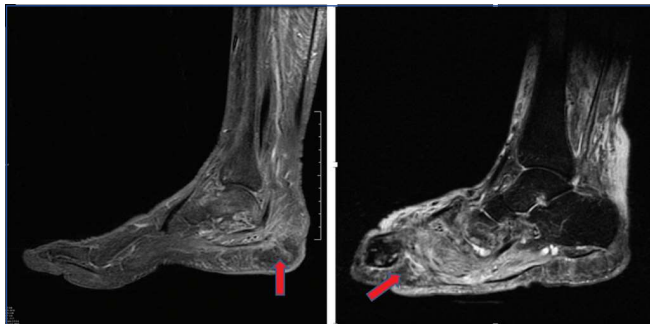


frequently associated with osteomyelitis, due to contiguous spread of infection from skin [5,10,11]. Careful inspection may reveal a sinus tract travelling from the cutaneous plane and extending to the bone. The presence of it can improve the overall diagnostic accuracy. Infection is unlikely when there is no soft tissue change adjoining the bone marrow signal abnormalities.

Nine cases of charcot had soft tissue changes. In early stages of neuroarthropathy there is co-existent soft tissue oedema and fluid collection. However, lack of skin ulceration and sinus tract is indicative of charcot. Another study by Clouse ME et al., and Brower AC et al., had showed that there are no substantial soft tissue changes in charcot since the foot is deformed and hence ulcers/sinus tracts are less common [12,13].

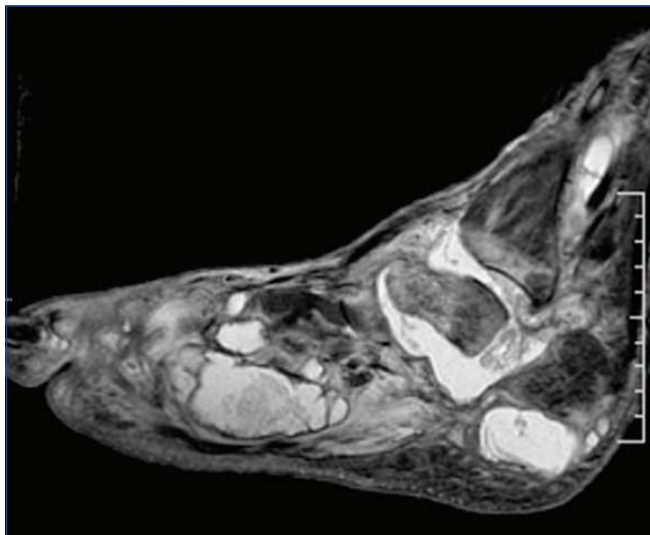
#### 6. Bone marrow signal changes in osteomyelitis and charcot:

Tan PL and Teh J in their study of pictorial review of MRI foot suggested that STIR sequence can overestimate the true extent of infection especially if there is overlap of osteomyelitis with charcot [Table/Fig-17,18] or septic arthritis [1]. Other conditions like fracture and infarction can also result in altered marrow signal. Marcus CD et al., study also showed that signal intensity changes within the bone marrow are commonly observed in the diabetic foot and are non specific in differentiating osteomyelitis and charcot [3].



**[Table/Fig-16]:** Sinus tract with "tram track" pattern and osteomyelitis. Sagittal T1 post contrast images demonstrating an enhancing deep sinus tract (arrow) extending down to the calcaneum. There is abnormal signal in underlying bone marrow indicating osteomyelitis.

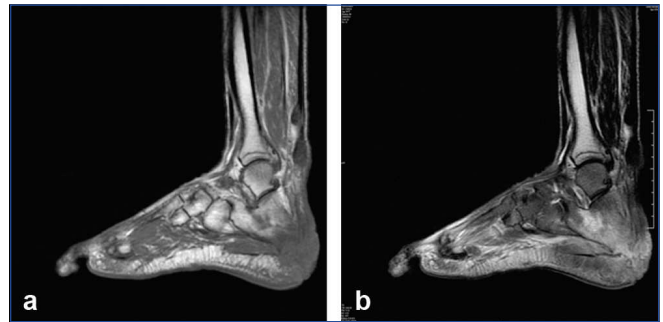**[Table/Fig-17]:** Sagittal STIR images showing stump osteomyelitis (arrow) involving the metatarsals in a patient with neuropathic osteoarthropathy with distal foot amputation. (Images from left to right)



**[Table/Fig-18]:** Sagittal STIR image showing multiple abscesses which appears to be communicating with the joint in a case of case of severely deformed charcot foot.

Majority of the cases in osteomyelitis (75.9%) and Charcot (84.2%) showed low signal intensities in T1 weighted images [Table/Fig-19a,b]. This was found to be non specific for differentiating the two conditions. The p-values obtained were also not very significant, (p-value was 0.719 for osteomyelitis and charcot on MRI) making

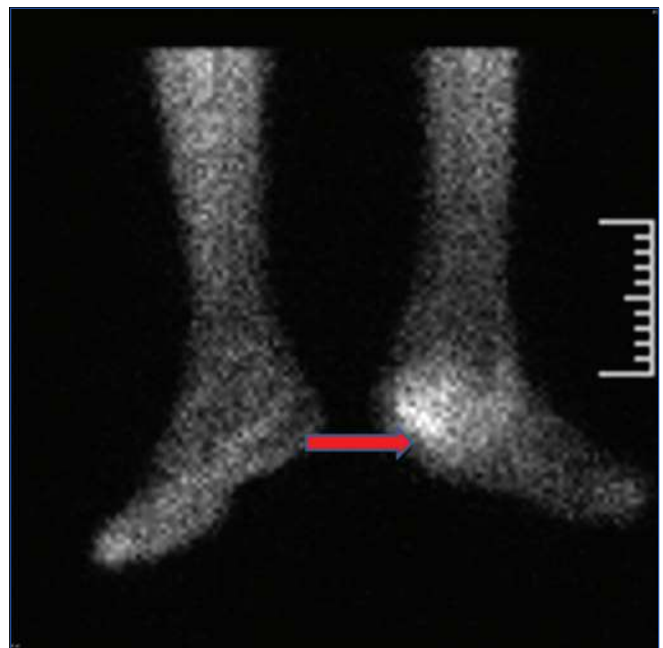
this variable an unreliable indicator. Decreased marrow signal intensity on T1 weighted images and increased marrow intensity on T2 weighted images were seen in both acute evolving neuropathic arthropathy and osteomyelitis. Although several studies have indicated the significance of marrow signal changes in differentiating osteomyelitis from charcot [13,14], present study could not find out a significant correlation between the signal intensities.



**[Table/Fig-19a,b]:** Showing the sagittal T1 weighted image with hypointense signal in metatarsal (forefoot) and calcaneum (hindfoot) and the corresponding T2 weighted sagittal image (b) showing hyperintense signal suggestive of oedema in a case of osteomyelitis.

MRI showed Sensitivity of 83.3%, specificity of 77.8%, along with positive and negative predictive value of 86.20% and 73.68%, respectively and the accuracy is about 81.25%, which was in concordance with previous study of MRI in diabetic pedal osteomyelitis with sensitivity and specificity of 90% and 83%, respectively [1].

The sensitivity in this study was decreased (83.3%) because of the false negative cases (5 out of 30 cases of proven OM). In all these five cases, there was deformity along with both midfoot/hindfoot involvement and oedema pattern involving several bones and joints, hence it was given as charcot, but microscopy showed growth favouring charcot with superadded osteomyelitis. In a setting of chronic neuroarthropathy with deformity plain MRI has got its own limitations in predicting a superadded osteomyelitis. There was no growth in four cases which were diagnosed as osteomyelitis by MRI. It was given as osteomyelitis because of the alterations in marrow signal and diffuse bone marrow involvement, but these cases turned out to be acute charcot on biopsy/PET scan [Table/Fig-20] thereby decreasing the specificity of differentiating charcot and osteomyelitis.



**[Table/Fig-20]:** PET scan showing significant tracer uptake (arrow) in the left calcaneum in the case of calcaneal osteomyelitis.

Four of the cases it was given as no charcot turned out to be charcot. This reduced the specificity in charcot. All these cases turned out to be acute charcot with soft tissue oedema. Five cases out of 19 cases diagnosed as charcot by MRI showed growth and all these cases had deformity and features of chronic neuropathic arthropathy. As described earlier there is no reliable method for making the distinction between these two i.e., in a setting of osteomyelitis with charcot.

Earlier study conducted by Ahmadi ME et al., also showed similar problems, in those cases bone biopsy remains main diagnostic method [14]. Problems which are encountered were acute charcot mimicking osteomyelitis and cases of charcot with superadded infection in which the distribution and oedema pattern were found to be helpful in differentiating these entities.

Currently, anti-resorptive drugs are used in treatment and in future Dynamic contrast MRI (D-MRI) [7]. In future dynamic contrast MRI will be adding value in finding out level of activity of acute charcot foot, monitoring treatment response and predicting healing time. Various studies are being done to evaluate the use of dynamic contrast MRI for evaluation of treatment in charcot and studies are showing that contrast medium uptake obtained at D-MRI represents reproducible parameters that are reliable for predicting and monitoring treatment outcome in acute charcot foot.

### Limitation(s)

Majority of the diabetic patients had concomitant chronic kidney disease in which contrast injection of gadolinium was avoided because of the potential gadolinium induced nephrogenic systemic fibrosis. The American College of Radiology (ACR) recommends that gadolinium based contrast material not to be administered to patients with a severely reduced Glomerular Filtration Rate (GFR) (<30 mL/min/1.73 m<sup>2</sup>).

### CONCLUSION(S)

The MRI criteria was found to be reliable in identifying osteomyelitis. Absence of deformity, forefoot/hindfoot locations, presence of soft tissue like ulcer/sinus tract/abscess and fistulas, focal single bone involvement along with diffuse marrow oedema pattern were all in favour of osteomyelitis. Sensitivity and specificity of MRI criteria in

charcot was found to be 77.8% and 83.3%, respectively. Involvement of several bones and joints along with sub chondral/periarticular locations, presence of deformity, absence of soft tissue changes and mid foot locations were all in favour of charcot.

### Acknowledgement

Professional and technical personnel of Amrita Institute of Medical Sciences, Kochi, Kerala, India.

### REFERENCES

- [1] Tan PL, Teh J. MRI of the diabetic foot: Differentiation of infection from neuropathic change. *Br J Radiol.* 2007;80(959):939-48.
- [2] Rogers LC, Frykberg RG, Armstrong DG, Boulton AJ, Edmonds M, Van GH, et al. The Charcot foot in diabetes. *Diabetes Care.* 2011;34(9):2123-2129.
- [3] Marcus CD, Ladam-Marcus VJ, Leone J, Malgrange D, Bonnet-Gausserand FM, Menanteau BP. MR imaging of osteomyelitis and neuropathic osteoarthropathy in the feet of diabetics. *Radiographics.* 1996;16:1337-48.
- [4] Papanas N, Zissimopoulos A, Maltezos E. (18) F-FDG PET and PET/CT for the diagnosis of diabetic foot osteomyelitis. *Hippokratia.* 2013;17(1):04-06.
- [5] Morrison WB, Schweitzer ME, Batte WG, Radack DP, Russel KM. Osteomyelitis of the foot: Relative importance of primary and secondary MR imaging signs. *Radiology.* 1998;207:625-32.
- [6] Enderle MD, Coerper S, Schweitzer HP, Kopp AE, Thelen MH, Meisner C, et al. Correlation of imaging techniques to histopathology in patients with diabetic foot syndrome and clinical suspicion of chronic osteomyelitis. The role of high-resolution ultrasound. *Diabetes Care.* 1999;22(2):294-99.
- [7] Zampa V, Bargellini I, Rizzo L, Turini F, Ortori S, Piaggese A, et al. Role of dynamic MRI in the follow-up of acute charcot foot in patients with diabetes mellitus. *Skeletal Radiology.* 2011;40:991-99.
- [8] Ledermann HP, Morrison WB, Schweitzer ME. MR image analysis of pedal osteomyelitis: Distribution, patterns of spread, and frequency of associated ulceration and septic arthritis. *Radiology.* 2002;223:747-55.
- [9] Donovan A, Schweitzer ME. Use of MR imaging in diagnosing diabetes-related pedal osteomyelitis. *Radiographics.* 2010;30(3):723-36.
- [10] Tang JS, Gold RH, Bassett LW, Seeger LL. Musculoskeletal infection of the extremities: Evaluation with MR imaging. *Radiology.* 1988;166:205-09.
- [11] Craig JG, Amin MB, Wu K, Eyer WR, van Holsbeeck MT, Bouffard JA, et al. Osteomyelitis of the diabetic foot: MR imaging-pathologic correlation. *Radiology.* 1997;203:849-55.
- [12] Clouse ME, Gramm HF, Legg M, Flood T. Diabetic osteoarthropathy. Clinical and roentrographic observations in 90 cases. *Am J Roentgenol Radium TherNuel Med.* 1974;121:22-34.
- [13] Brower AC, Allman RM. Pathogenesis of the neuropathic joint: Neurotraumatic vs neurovascular. *Radiology.* 1981;139(2):349-54.
- [14] Ahmadi ME, Morrison WB, Carrino JA, Schweitzer ME, Raikin SM, Ledermann HP. Neuropathic arthropathy of the foot with and without superimposed osteomyelitis: MR imaging characteristics. *Radiology.* 2006;203:849-55.

#### PARTICULARS OF CONTRIBUTORS:

1. Assistant Professor, Department of Radiodiagnosis, Aarupadai Veedu Medical College, Puducherry, India.
2. Assistant Professor, Department of Radiodiagnosis, Christian Medical College, Vellore, Tamil Nadu, India.
3. Professor, Department of Radiodiagnosis, Amrita Institute of Medical Sciences, Kochi, Kerala, India.
4. Professor and Head, Department of Radiodiagnosis, Amrita Institute of Medical Sciences, Kochi, Kerala, India.
5. Associate Professor, Department of Pharmacology, Mahatma Gandhi Medical College and Research Institute, Puducherry, India.

#### NAME, ADDRESS, E-MAIL ID OF THE CORRESPONDING AUTHOR:

Dr. Uma Narayanamurthy,  
No. 7a, Shiradi Nivas, Dhanalakshmi Nagar Extension, Gundusalai, Semmandalam,  
Cuddalore-607001, Puducherry, India.  
E-mail: numa.lally@gmail.com

#### PLAGIARISM CHECKING METHODS: [Lian H et al.]

- Plagiarism X-checker: Jul 23, 2021
- Manual Googling: Nov 23, 2021
- iThenticate Software: Dec 20, 2021 (20%)

#### ETYMOLOGY: Author Origin

#### AUTHOR DECLARATION:

- Financial or Other Competing Interests: None
- Was Ethics Committee Approval obtained for this study? Yes
- Was informed consent obtained from the subjects involved in the study? Yes
- For any images presented appropriate consent has been obtained from the subjects. Yes

Date of Submission: **Jul 21, 2021**  
Date of Peer Review: **Aug 27, 2021**  
Date of Acceptance: **Nov 23, 2021**  
Date of Publishing: **Jan 01, 2022**